

Reprinted from

AJO-DO



Volume 133

Number 2

FEBRUARY 2008

American Journal of Orthodontics
& Dentofacial Orthopedics

Orthodontic Intervention in the Early Mixed Dentition: A Prospective, Controlled Study on the Effects of the Eruption Guidance Appliance

Katri Keski-Nisula, Riitta Hernesniemi, Maritta Heiskanen, Leo Keski-Nisula,
and Juha Varrela

OFFICIAL PUBLICATION OF THE
American Association of Orthodontists, its constituent societies, the American Board of Orthodontics,
and the College of Diplomates of the American Board of Orthodontics

PUBLISHED BY
Mosby, Inc

WWW.MOSBY.COM/AJODO



Orthodontic intervention in the early mixed dentition: A prospective, controlled study on the effects of the eruption guidance appliance

Katri Keski-Nisula,^a Riitta Hernesniemi,^b Maritta Heiskanen,^c Leo Keski-Nisula,^d and Juha Varrela^e

Vaasa, Kurikka, Jalasjärvi, Tampere, and Turku, Finland

Introduction: A prospective, controlled cohort study was started in 1998 to investigate the effects of orthodontic treatment in the early mixed dentition with the eruption guidance appliance. **Methods:** Occlusal changes were recorded in 167 treated children and 104 controls after they had reached the middle mixed-dentition stage. Treatment began when the first deciduous incisor was exfoliated (T1) and ended when all permanent incisors and first molars were fully erupted (T2). The children's mean ages were 5.1 years (SD 0.5) at T1 and 8.4 years (SD 0.5) at T2. **Results:** From T1 to T2, overjet in the treatment group decreased from 3.1 to 1.9 mm and overbite from 3.2 to 2.1 mm. In the control group, overjet increased from 2.9 to 4.1 mm and overbite from 3.3 to 4.1 mm. At T2, the differences between the groups were highly significant ($P < .001$). At T1, 18% of the children in the treatment group and 22% of the controls had tooth-to-tooth contact between the maxillary and mandibular incisors. All others had an open bite, or the mandibular incisors were in contact with the palatal gingiva. At T2, tooth-to-tooth contact was observed in 99% of the treated children and 24% of the controls ($P < .001$). Almost half of children in both groups showed incisor crowding at T1. Good alignment of the incisors was observed in 98% of the treated children at T2, whereas maxillary crowding was found in 32% and mandibular crowding in 47% of the controls ($P < .001$). At T1, 41% of the children in the treatment group and 53% of the controls had a Class I relationship; the rest had either a unilateral or a bilateral Class II relationship. At T2, a Class I relationship was found in 90% of the treated children and 48% of the controls ($P < .001$). At least 1 occlusal deviation, including overjet ≥ 5 mm, overbite ≥ 5 mm, open bite, gingival contact of the mandibular incisors, crowding, or Class II relationship, was observed in 13% of the treated children, but the deviations were mild, and no child was considered to need treatment. In the control group, 88% of the children showed at least 1 occlusal deviation ($P < .001$). **Conclusions:** Treatment in the early mixed dentition with the eruption guidance appliance is an effective method to restore normal occlusion and eliminate the need for further orthodontic treatment. Only a few spontaneous corrective changes can be expected without active intervention. (*Am J Orthod Dentofacial Orthop* 2008;133:254-60)

Timing of treatment is a controversial area in orthodontics. Opinions among clinicians show great diversity; some recommend intervention in the early stages of occlusal development, and others

argue in favor of treatment in the late mixed or early permanent dentition. It has been suggested that, although almost all types of malocclusion could benefit from early treatment, the effectiveness of intervention depends on malocclusion.¹ For example, treatment of posterior crossbite in the deciduous or early mixed dentition is generally considered more beneficial than early correction of a Class II relationship. The main reason for the controversy seems to be that our present knowledge about the timing of treatment is largely based on clinical experience and reflects various approaches and clinical traditions of orthodontic practice. Scientific evidence is limited, and few studies have specifically targeted questions about the effects of early treatment.

Clinical trials in the United States²⁻⁴ and the United Kingdom⁵ focused on the effectiveness of 2 alternative treatment modalities in Class II treatment. In these

^aChief orthodontist, Vaasa Central Hospital, Vaasa, Finland.

^bGeneral practitioner, Kurikka Health Center, Kurikka, Finland.

^cGeneral practitioner, Jalasjärvi Health Center, Jalasjärvi, Finland.

^dAssistant professor, Department of Radiology, Tampere University Hospital, Tampere, Finland.

^eProfessor and chair, Department of Oral Development and Orthodontics; director, Postgraduate School of Oral Health Sciences; vice dean, Institute of Dentistry, University of Turku, Turku, Finland.

Supported by the Finnish Dental Society Apollonia, the Medical Research Fund of Turku University Central Hospital, the Medical Research Fund of Vaasa Hospital District, and Plandent Oyj.

Reprint requests to: Juha Varrela, Department of Oral Development and Orthodontics, Institute of Dentistry, University of Turku, Lemminkäisenkatu 2, FIN-20520 Turku, Finland; e-mail, juha.varrela@utu.fi.

Submitted, February 2006; revised and accepted, May 2006.

0889-5406/\$34.00

Copyright © 2008 by the American Association of Orthodontists.

doi:10.1016/j.ajodo.2006.05.039

trials, 2-phase treatment that included an early growth modification phase and a second phase was compared with single-phase treatment in the early permanent dentition. The results showed that, apart from improved self-esteem, only minor benefits were obtained by the early treatment phase.⁶ These studies provided valuable scientific evidence for clinical decision making, particularly when considering 2-phase treatment protocols. However, only a few treatment modalities and appliances were studied, and any generalizations drawn from the results should be limited to these. For example, rather low forces were used in the activation of the headgear. A similar growth-modification phase with higher orthopedic forces could have resulted in better and more consistent effects, as indicated by the findings of Kirjavainen et al⁷⁻⁹ and Mäntysaari et al.¹⁰ Furthermore, only a few of the children in the trials started the growth modification phase in the early mixed dentition.²⁻⁵ Many questions therefore remain about the effectiveness of orthodontic intervention in the mixed dentition.

In Finland, where orthodontics is included in the public dental care, treatment modalities that emphasize early intervention are becoming increasingly popular.¹¹⁻¹³ After screening of malocclusions in the deciduous dentition, treatment is frequently started in the early mixed or, in some cases, even in the late deciduous dentition; appliances typically include expansive arches, orthopedic headgear, activators, and activator-type appliances.¹² Clinical experience suggests that systematic early intervention offers advantages in a publicly funded health care system. For example, treatment can be offered to more children without extra manpower or cost increases.^{12,13} Recently, the eruption guidance appliance has been used more often in the orthodontic clinics focusing on early treatment.¹² This appliance has many indications and has been found to be effective in the treatment of many malocclusions including crowding, deepbite, excessive overjet, and distal bite. In addition, the eruption guidance appliance normally requires only minimal adjustments, allowing less chair-side time and longer intervals between check-ups. Furthermore, retention can be carried out with the same appliance as the treatment. Clinical experience indicates good and stable results.

A clinical investigation was started in 1998 in 2 municipalities in western Finland, Jalasjärvi and Kurikka. Orthodontic care in the dental clinics of these cities is based on comprehensive early treatment; most patients are treated in the early mixed dentition with the eruption guidance appliance as the main therapeutic device. Children with a skeletal Class III relationship and those with a posterior crossbite are usually treated

in the deciduous dentition, the former with a combination of expansive appliance and facemask, and the latter with a quad-helix appliance. Other appliances—eg, Van Beek activator—are used occasionally.

Our goal in this prospective, controlled cohort study was to investigate the treatment effects of the eruption guidance appliance. Early treatment was studied in a real-world situation where the established treatment protocols were followed with only minor adjustments, mainly to ensure timely and controlled data collection. Ethical, practical, and financial restrictions prevented random assignment of the participants into treatment and follow-up groups in each municipality. The neighboring town of Seinäjoki, where orthodontic treatment is not given until the late mixed dentition, agreed to provide untreated control subjects for the study. Matching of the treatment and control groups was achieved by using large unselected and representative samples.

We describe the occlusal findings in 167 children treated in the early mixed dentition using the eruption guidance appliance as the only therapeutic device. The treatment effects were compared with the spontaneous changes in the occlusion of 104 control children during the same period—ie, the period that started when the first deciduous incisor was exfoliated (T1) and ended when all permanent incisors and first molars were fully erupted (T2).

MATERIAL AND METHODS

The treatment group was derived from the entire 1992 and 1993 age cohorts in Jalasjärvi (population, 9000) and the 1992 age cohort in Kurikka (population, 11,000). All children were screened in the late deciduous dentition, and a full clinical examination was made at the onset of the mixed dentition period of those who were considered to potentially need treatment. Children with at least 1 of the following occlusal characteristics were included: (1) distal step of ≥ 1 mm, (2) Class II canine relationship of ≥ 1 mm, (3) crowding, (4) overjet of ≥ 3 mm and lack of tooth-to-tooth contact between the incisors, (5) overbite of ≥ 3 mm and lack of tooth-to-tooth contact between the incisors, (6) anterior crossbite, and (7) buccal crossbite (scissorsbite).

The number of children fulfilling these criteria was 315. Of them, 33 were treated with other appliances, mainly the quad-helix, and they were excluded from the study sample. In 27 cases, the child or the family refused orthodontic treatment. Treatment with an eruption guidance appliance was started in 255 children. During the treatment, 12 children moved to another municipality and could not complete the treatment; their records were excluded from the analysis. Of the

remaining 243 children, 167 completed the treatment successfully.

Seventy-six children (31%) were excluded from the study because they did not wear the appliance. The reasons for difficulties in cooperation were mostly psychosocial. In these patients, treatment was terminated when it became clear that the children did not cooperate, usually within a few months after starting treatment. In 3 patients, a serious illness prevented the completion of the orthodontic treatment. No further records of these children were collected or included in the analyses.

A random sample of 104 children from the same 1992 and 1993 age cohorts in Seinäjoki (population, 30,000) who fulfilled the inclusion criteria formed the control group. The ethnic background of all children in the treatment and control samples was Finnish. All were healthy, and none had had earlier orthodontic treatment. All treatment and control children and their parents were free to decline their participation in the study at any time.

The timing of all examinations and interventions throughout the study was based on each child's stage of dental development rather than on chronologic age. The treatment began immediately after the clinical examination at T1, the beginning of the mixed dentition period, defined as the time immediately after the exfoliation of the first deciduous tooth. The evaluations of the occlusal changes in the treatment and control groups were made at T2, after full eruption of all permanent incisors and first molars. At this point, the early treatment group entered the retention period, and treatment was started in the control group.

We analyzed the occlusal changes from T1 to T2 of 167 children in the treatment group (85 boys, 82 girls) and 104 children in the control group (52 boys, 52 girls). The mean ages in both groups were 5.1 years (SD 0.5) at T1 and 8.4 years (SD 0.5) at T2.

Two or 3 prefabricated eruption guidance appliances (Nite-Guide or Occlus-o-Guide; Ortho-Tain, Winnetka, Ill) were used in each patient (Fig). A Nite-Guide was the first appliance in only a few patients whose first permanent molars had not yet started to erupt. The appropriate size of the appliance was determined as recommended by the manufacturer. The appliances were worn during the night only. If difficulties were encountered, daytime wear of 1 hour was recommended until the problems with night wear disappeared. Active treatment was defined as the time between T1 and T2. The average duration of active treatment was 3.3 years. At T2, all treated children entered the retention period, when the last of the 2 or 3 appliances was used as a retainer, 2 nights a week. The

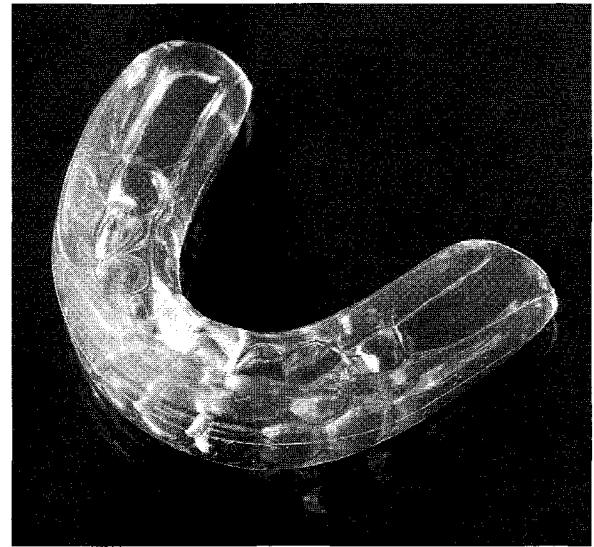


Fig. Eruption guidance appliance (Occlus-o-Guide).

retention was to be continued until all permanent canines, premolars, and second molars were fully erupted. Appointments were every 12 weeks during the active period and once every 6 months during the retention period.

Full clinical examinations, including collecting of dental casts, of all children were carried out at T1 and T2. Overbite and overjet were measured directly in the mouth with the mandible manipulated in centric relation as described earlier.¹⁴ The measurement was taken between the mandibular and maxillary right central incisors, as suggested by Moorrees,¹⁵ by using a metal ruler with accuracy of 0.1 mm. The values for overbite in the deciduous dentition were not corrected for incisal wear. The type of contact of the mandibular incisors to the maxilla was also registered directly in the mouth with the mandible in centric relation; it was classified as *tooth-to-tooth contact* when contact with the maxillary incisors was established, *gingival contact* when the mandibular incisors contacted the palatal gingiva or mucosa, and *open contact* when an open bite was present. Crowding in the anterior segment was assessed from the dental casts by registering overlapping teeth. The terminal plane relationship was measured from the dental casts, trimmed to centric relation, between perpendicular projections, on the occlusal plane, from the distal surfaces of the maxillary and mandibular second deciduous molars as suggested by Bishara et al.¹⁶ A child was considered to have a Class II relationship with a distal step of ≥ 1 mm. The terminal plane relationship of the second deciduous molars was used

Table I. Overjet and overbite at T1 and T2

	Treatment group (n = 167)		Control group (n = 104)		P	95% CI
	Mean	SD	Mean	SD		
Overjet						
T1	3.1	1.4	2.9	1.8	>.05	-0.19 to 0.63
T2	1.9	0.7	4.1	1.9	<.001	-2.51 to -1.76
Overbite						
T1	3.2	1.7	3.3	1.9	>.05	-0.55 to 0.35
T2	2.1	0.9	4.1	1.3	<.001	-2.41 to -1.62

to classify the occlusion as Class I or Class II at T1 and T2. Analogously, the distance from the tip of the maxillary canine to the contact point between the mandibular canine and first molar on the occlusal plane was measured.

All dental assessments and measurements were performed by the first author (K.K.N.). The measurements were made with a digital caliper to the nearest 0.01 mm. Method error for the measurements, assessed by means of the standard error of a single determination on repeated measurements of 30 randomly selected subjects, was 0.14 mm.¹⁷ In the statistical assessment, the chi-square test and the *t* test were used. *P* values less than .05 were considered statistically significant.

RESULTS

At T1, overjet varied from -2 to 10 mm and overbite from -3 to 7 mm; no statistically significant difference was found between the groups (Table I). Changes in overjet from T1 to T2 were -1.2 mm (SD 1.6) in the treatment group and 1.2 mm (SD 1.5) in the control group. The difference in overjet between the groups from T1 to T2 was highly significant (*P* <.001). Changes in overbite from T1 to T2 were -1.1 mm (SD 1.9) in the treatment group and 0.9 mm (SD 1.3) in the control group; this difference was highly significant (*P* <.001).

The contact point of the mandibular incisors was registered at centric relation at T1 and T2. At T1, tooth-to-tooth contact was found in 30 children (18%) in the treatment group and 23 children (22%) in the control group; all others had an open bite, or the mandibular incisors were in contact with the maxillary gingival or palatal mucosa. At T2, 165 of the treated children (99%) and 25 control children (24%) showed tooth-to-tooth contact between incisors (*P* <.001). In the treatment group, 50 children (30%) had gingival contact, and 86 (51%) had an open bite at T1. At T2, a mild open bite persisted in 2 treated children. In the control group, the situation did not change significantly from T1 to T2. Gingival contact was observed in 50

Table II. Incisor crowding at T1 and T2

	Treatment group (n = 167)	Control group (n = 104)	P
Maxilla			
T1	19 (11%)	9 (9%)	>.05
T2	3 (2%)	33 (32%)	<.001
Mandible			
T1	80 (48%)	46 (44%)	>.05
T2	2 (1%)	49 (47%)	<.001

control children (48%) at T1 and in 42 (40%) at T2. The respective figures for open bite were 31 (30%) and 37 (36%).

The treatment and control groups showed similar figures for crowding at T1 (Table II). At T2, all but 4 children in the treatment group showed well-aligned incisors; mild crowding was still present in the mandible of 1 child, in the maxilla of 2 children, and in both jaws of 1 child. The control children had significantly more crowding at T2 (*P* <.001).

The mean sagittal relationship of the canines at T1 indicated a Class II tendency in both groups: 1.6 mm (SD 1.5) in the treatment group and 1.4 mm (SD 1.7) in the control group. The difference was statistically nonsignificant (*P* = .25; 95% CI -0.12 to 0.44). At T2, the canine relationship had decreased to 0.2 mm (SD 0.7) in the treatment group but remained at 1.4 mm (SD 1.6) in the control group. The difference at T2 was highly significant (*P* <.001; 95% CI -1.49 to -1.04).

The mean terminal plane relationship at T1 showed a slight distal tendency in both groups: 0.7 mm (SD 1.7) in the treatment group and 0.5 mm (SD 1.7) in the control group. The difference was not statistically significant (*P* = .20; 95% CI 0.2 to 0.48). At T2, the terminal plane relationships had changed to -1.3 mm (SD 1.2) in the treatment group and 0.4 mm (SD 1.9) in the control group. The difference at T2 was highly significant (*P* <.001; 95% CI -1.91 to -1.34). The numbers of children with Class I, Class I/Class II, and Class II relationships are shown in Table III. The

Table III. Sagittal relationship of the posterior segments at T1 and T2

	Treatment group (n = 167)	Control group (n = 104)	P
Class I			
T1	68 (41%)	55 (53%)	>.05
T2	151 (90%)	50 (48%)	<.001
Class I/II			
T1	33 (20%)	18 (17%)	>.05
T2	11 (7%)	18 (17%)	<.001
Class II			
T1	66 (40%)	31 (30%)	>.05
T2	5 (3%)	36 (35%)	<.001

Table IV. Frequencies of deviating occlusal characteristics at T2

	Treatment group (n = 167)	Control group (n = 104)
Overjet \geq 5 mm	0 (0%)	31 (30%)
Overbite \geq 5 mm	1 (1%)	40 (38%)
Open bite	2 (1%)	37 (36%)
Gingival contact of mandibular incisors	0 (0%)	42 (40%)
Maxillary crowding	3 (2%)	33 (32%)
Mandibular crowding	2 (1%)	49 (47%)
Unilateral Class II	11 (7%)	18 (17%)
Bilateral Class II	5 (3%)	36 (35%)

The difference in the distribution of the characteristics between the groups is highly significant ($P < .001$).

distribution in the treatment and control groups was not significantly different at T1 ($P = .14$). A highly significant difference was found at T2 ($P < .001$).

Table IV shows the frequencies of deviating occlusal characteristics, including overjet \geq 5 mm, overbite \geq 5 mm, open bite, gingival contact of the mandibular incisors, crowding, and Class II relationship at T2. The numbers of children in the treatment and control groups with at least 1 deviation in the middle mixed dentition were 22 (13%) and 91 (88%), respectively.

DISCUSSION

The guidelines for orthodontic treatment at the dental clinics of Jalasjärvi and Kurikka are designed to outline a comprehensive early treatment protocol. Potential malocclusion cases are screened and diagnosed in the deciduous dentition. Depending on the type of the malocclusion, treatment is started either in the deciduous dentition or at the beginning of the mixed dentition. A similar approach to early treatment was described by Dugoni,¹⁸ although the suggested time to start the treatment was later in the mixed dentition, between 7 and 9 years of age. Early diagnosis of

malocclusions is largely based on the deciduous occlusion, and, in most cases, it is straightforward.¹⁴ Early treatment at Jalasjärvi and Kurikka is intended to be 1 phase—ie, the treatment plan does not normally include a second phase of treatment. Conditions that cannot be detected early, such as congenitally missing premolars, ectopically erupting molars, and impacted canines are diagnosed and treated later.

Our findings indicate that significant improvement in the occlusion was achieved with early intervention. After reaching the middle mixed-dentition stage, most treated children showed favorable intermaxillary relationships in the incisor, canine, and molar segments. Overbite and overjet were both close to 2 mm, the incisors had tooth-to-tooth contact and good alignment, a mesial step was established in the molar region, and the canines showed almost full Class I relationships. As shown by Table IV, the need for further treatment had markedly decreased through the intervention. Only 22 (13%) of the 167 children in the treatment group had persisting mild deviations. None of these children was considered to need further treatment at this point. In the control group, on the other hand, 92 (88%) of the 104 children had at least 1 deviating occlusal characteristic. Early orthodontic intervention is frequently opposed on the basis of findings that occlusal development can show spontaneous correction in a growing child.¹⁵ However, the results in the control group indicate that this is the exception rather than the rule. During the observation period from early to middle mixed dentition, the frequencies of the occlusal deviations remained relatively unchanged in the control group.

In our sample, the time from T1 to T2 was 3.3 years. Because the eruption guidance appliance was used to guide the erupting permanent teeth to their correct positions in the dental arches, the length of the active treatment period was the same. On the other hand, the total chair-side time that was required for the completion of the treatment was relatively short because routine checkups, every 12 weeks, normally took no more than 5 to 10 minutes each. An advantage of the eruption guidance appliance is that it not only guides the eruption of the teeth but also simultaneously acts on the transversal, sagittal, and vertical relationships of both dental arches.

Several attempts were previously made to reduce or eliminate malocclusion by early interceptive measures with and without appliance therapy.^{13,19-23} Although all investigations reported beneficial effects, the results were variable, probably reflecting the diversity of the interceptive protocols and the wide age ranges of the children. Two studies were carried out in countries where orthodontic treatment is publicly subsidized.^{13,23}

Those findings indicated that early interceptive measures, when applied in the community, can result in significant reductions in treatment needs.^{13,23} A similar but even more extensive improvement of the occlusion was observed in our study.

The prefabricated eruption guidance appliance we studied has wide treatment indications, but it is usually recommended for mild to moderate malocclusions only.²⁴ However, clinical experience has shown that, if treatment is started in the early mixed dentition, the severity of the malocclusion seldom appears to be a contraindication. At this stage of occlusal development, almost all cases can be considered as mild or moderate and are therefore suitable for treatment with the appliance. The eruption guidance appliance is designed to guide the erupting teeth into the correct positions before the fibers of the periodontal ligament mature.²⁵ By starting active treatment at the onset of the mixed dentition period, as in this investigation, the action of the appliance can be exerted on all permanent incisors and first molars.

Although the effectiveness of the eruption guidance appliance is not limited to the period of active eruption, clinical experience indicates that treatment tends to become more complicated if it is started later.²⁶ After maturation of the periodontal ligament, daytime wear is regularly needed to achieve the desired effect because tooth movement requires higher forces and longer treatment times. Often, combined treatment with other appliances such as headgear, rapid palatal expansion, or fixed appliances might be necessary.²⁷ On the other hand, if treatment is carried out during the active eruption of the teeth, the appliance seems to be effective in most patients.

Parental guidance and support are always essential when treating young children with removable appliances, particularly at the beginning of the treatment. Of the children in this study who completed the treatment successfully, 4 had problems with the appliance at the beginning, but they overcame the difficulties quickly. On the other hand, treatment of 76 children (31%) had to be discontinued because of persistent problems with compliance, because either the child was not willing to wear the appliance or the parents were not motivated enough to support the child. Various psychosocial disturbances in the families of these children were the main reasons for poor cooperation. Our rate of non-compliance was somewhat higher than reported for the Twin-block appliance⁵ and about the same as the Fränkel appliance.² It has been suggested that young age of the patients would be a major limiting factor for early treatment in the community.²⁸ Our findings indicate that family background seems to be the single most

important factor affecting compliance, not the age of the patients per se. In spite of problems with cooperation, 43% of the children of the entire 1992 and 1993 age cohorts in Jalasjärvi and Kurikka were successfully treated with the eruption guidance appliance.

Intervention in the early mixed dentition with the eruption guidance appliance appears to be an effective method to reduce the need for orthodontic treatment. Clinical experience indicates that, with proper retention, treatment results remain good with little or no relapse. However, the long-term effectiveness of this treatment modality can be assessed only after the retention period and the out-of-retention follow-up.

CONCLUSIONS

The results indicate that orthodontic intervention with the eruption guidance appliance in the early mixed dentition is an effective treatment modality for malocclusions with Class II or Class II tendency, excess overjet, deepbite, open bite, crowding, anterior crossbite, or buccal crossbite. During the treatment, the erupting permanent incisors and first molars were guided into their correct positions in the dental arches. At the same time, intermaxillary relationships in the incisor, canine, and molar segments were largely corrected. During the observation period, only a few spontaneous corrective changes occurred in the control children. By the time the children reached the middle mixed dentition, little treatment need was left in the treatment group compared with the control group, where deviating occlusal characteristics were commonly observed.

We thank the staff, the patients, and their parents at the health centers of Jalasjärvi, Kurikka, and Seinäjoki for their cooperation and assistance.

REFERENCES

1. Bishara SE, Justus R, Graber TM. Proceedings of the workshop discussions on early treatment. *Am J Orthod Dentofacial Orthop* 1998;113:5-6.
2. Gafari J, Shofer FS, Jacobsson-Hunt U, Markowitz DL, Laster LL. Headgear versus function regulator in the early treatment of Class II, Division 1 malocclusion: a randomized clinical trial. *Am J Orthod Dentofacial Orthop* 1998;113:51-61.
3. Keeling SD, Wheeler TT, King GJ, Garvan CW, Cohen DA, Cabassa S, et al. Anteroposterior dental and skeletal changes after early Class II treatment with bionators and headgear. *Am J Orthod Dentofacial Orthop* 1998;113:40-50.
4. Tulloch JFC, Phillips C, Proffit WR. Benefit of early Class II treatment: progress report of a two-phase randomized clinical trial. *Am J Orthod Dentofacial Orthop* 1998;113:62-72.
5. O'Brien K, Wright J, Conboy F, Sanjic Y, Mandall N, Chadwick S, et al. Effectiveness of early orthodontic treatment with the Twin-block appliance: a multicenter, randomized, controlled

- trial. Part 1: dental and skeletal effects. *Am J Orthod Dentofacial Orthop* 2003;124:234-43.
6. O'Brien K, Wright J, Conboy F, Chadwick S, Connolly I, Cook P, et al. Effectiveness of early orthodontic treatment with the Twin-block appliance: a multicenter, randomized, controlled trial. Part 2: psychosocial effects. *Am J Orthod Dentofacial Orthop* 2003;124:488-95.
 7. Kirjavainen M, Kirjavainen T, Haavikko K. Changes in dental arch dimensions by use of an orthopedic cervical headgear in Class II correction. *Am J Orthod Dentofacial Orthop* 1997;111:59-66.
 8. Kirjavainen M, Kirjavainen T, Hurmerinta K, Haavikko K. Orthopedic cervical headgear with expanded inner bow in Class II correction. *Angle Orthod* 2000;70:317-25.
 9. Kirjavainen M, Kirjavainen T. Maxillary expansions in Class II correction with orthopedic cervical headgear. A posteroanterior cephalometric study. *Angle Orthod* 2003;73:281-5.
 10. Mäntysaari R, Kantomaa T, Pirttiniemi P, Pykäläinen A. The effects of early headgear treatment on dental arches and craniofacial morphology: a report of a 2 year randomized study. *Eur J Orthod* 2004;26:59-64.
 11. Pietilä T. Orthodontic care in Finnish health centers (dissertation). Turku, Finland: University of Turku; 1998.
 12. Pietilä T, Alanen P, Nordblad A, Kotilainen J, Pietilä I, Pirttiniemi P, et al. Hampaiden oikomishoito terveyskeskuksissa. Helsinki: Sosiaali- ja terveysalan tutkimus- ja kehittämiskeskus Stakes Raportteja 279; 2004.
 13. Väkiparta MK, Kerosuo HM, Nyström ME, Heikinheimo KA. Orthodontic treatment need from eight to 12 years of age in an early treatment oriented public health care system: a prospective study. *Angle Orthod* 2005;75:344-9.
 14. Keski-Nisula K, Lehto R, Lusa V, Keski-Nisula L, Varrela J. Occurrence of malocclusion and need of orthodontic treatment in early mixed dentition. *Am J Orthod Dentofacial Orthop* 2003;124:631-8.
 15. Moorrees CA. The dentition of the growing child. Cambridge, Mass: Harvard University Press; 1959.
 16. Bishara SE, Hoppens BJ, Jakobsen JR, Kohout FJ. Changes in the molar relationship between the deciduous and permanent dentitions: a longitudinal study. *Am J Orthod Dentofacial Orthop* 1988;93:19-28.
 17. Dahlberg G. Statistical methods for medical and biological students. London: George Allen and Unwin; 1948.
 18. Dugoni SA. Comprehensive mixed dentition treatment. *Am J Orthod Dentofacial Orthop* 1998;113:75-84.
 19. Popovich F, Thompson GW. Evaluation of preventive and interceptive treatment between three and eighteen years of age. In: Cook JT, editor. Transactions of the Third Orthodontic Congress; London; 1973 Aug 13-8. London: Crosby, Lockwood and Staples; 1975. p. 260-81.
 20. Freeman JD. Preventive and interceptive orthodontics: a critical review and results of a clinical study. *J Prev Dent* 1977;4:7-23.
 21. Ackerman JL, Proffit WR. Preventive and interceptive orthodontics: a strong theory proves weak in practice. *Angle Orthod* 1980;50:75-87.
 22. Hiles AM. Is orthodontic screening of 9-year-old children cost-effective? *Br Dent J* 1985;159:41-5.
 23. Al Nimri K, Richardson A. Interceptive orthodontics in the real world of community dentistry. *Int J Paediatr Dent* 2000;10:99-108.
 24. Bergersen EO. The eruption guidance myofunctional appliance: case selection, timing, motivation, indications and contraindications in its use. *Funct Orthod* 1985;2:17-33.
 25. Bergersen EO. The eruption guidance myofunctional appliance: how it works, how to use it. *Funct Orthod* 1984;1:28-35.
 26. Janson GRP, da Silva CCA, Bergersen EO, Henriques JFC, Pinzan A. Eruption guidance appliance effects in the treatment of Class II, division 1 malocclusions. *Am J Orthod Dentofacial Orthop* 2000;117:119-29.
 27. Kangaspeska M, Keski-Nisula K, Varrela J. Ortopedisen niska-vedon ja purenanohjaimen yhteiskäytöstä. *Suomen Hammaslääkärilehti* 2001; VIII n.s.: p. 742-7.
 28. White L. Early orthodontic intervention. *Am J Orthod Dentofacial Orthop* 1998;113:24-8.

TSP 58589



ELSEVIER

email: reprints@elsevier.comPlease visit www.elsevierreprints.com